

The diagram illustrates the life cycle of *Toxoplasma gondii*, showing the definitive host (cat) and various intermediate hosts (rodents, birds, humans, and other animals). It details the shedding of unsporulated oocysts in feces, the development of sporulated oocysts, and the subsequent infection of intermediate hosts through various routes (raw meat, litter boxes, contaminated food/water, and direct contact). The diagram also shows the parasite's development in these hosts and its eventual shedding back into the environment.

FACULTY OF MEDICINE, COLOMBO

FOUNDATION MODULE 2/ INFECTIOUS AND PARASITIC DISEASES MODULE

This manual has been designed to help you with your practical classes in Parasitology during the Foundation Module 2 and Infectious and Parasitic Diseases Module.

Brief descriptions of the medically important parasitic stages and gross specimens have been provided. However, it is by no means complete and should be supplemented by further reading of recommended textbooks in Parasitology.

Before starting any practical work:

Read the instructions

Listen to the demonstrator

Label all slides to be used

And if you have any doubts **ask** questions.

Prepared by:

Professor Deepika Fernando

Professor Sharmini Gunawardena

Dr. Sanath Senanayake

Technical Assistance

Ms. Himali Gunatilaka

Ms. Yasasmi Gnage

Ms. Sashika Dayananda

2nd March 2021

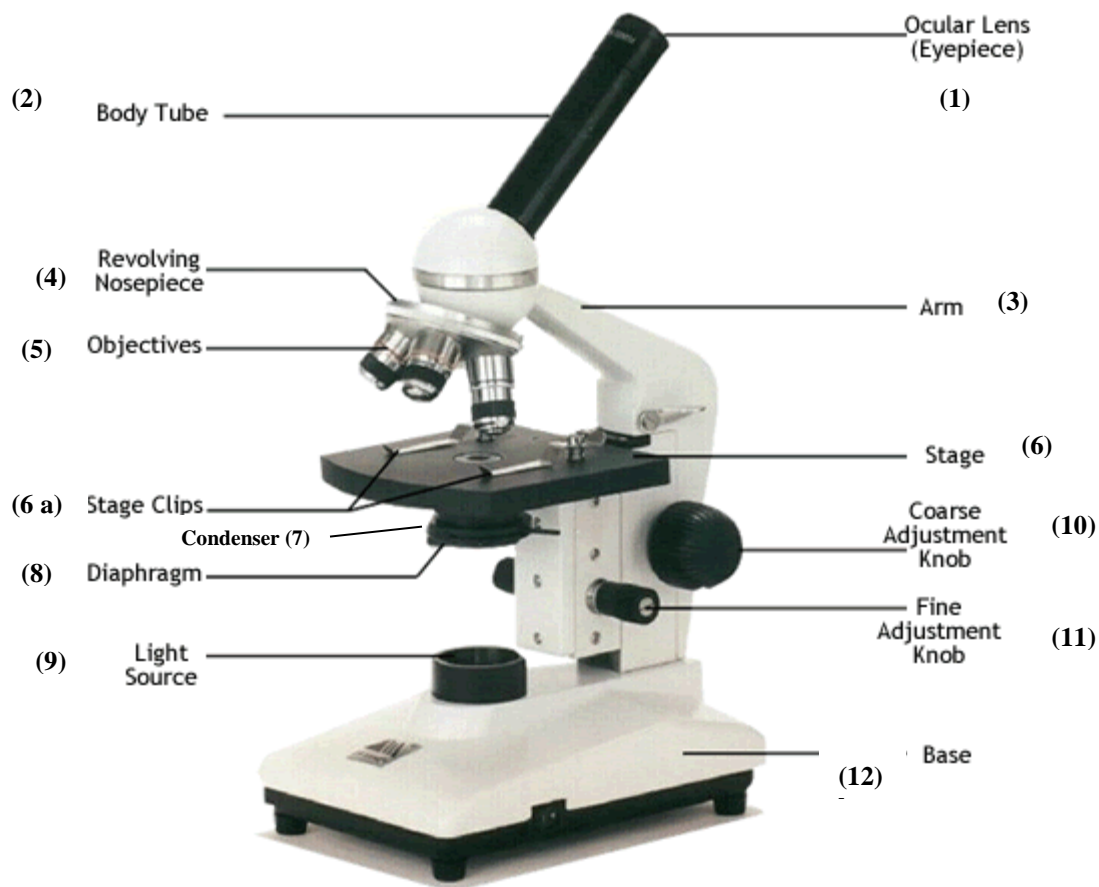
Contents	Page Number
PRACTICALS:	
Use of the Microscope	3
Malaria	6
Filariasis, Leishmaniasis, Toxoplasmosis and Trypanosomiasis	14
Intestinal and Urogenital Protozoa	16
Intestinal Nematodes, Cestodes and Trematodes	23
Medically important Arthropods	32
Snakes	38

PRACTICAL: USE OF THE MICROSCOPE

Introduction

The microscope is one of the most important instruments in a biology laboratory. There are many small objects such as the malaria parasites which cannot be seen by the unaided human eye. The microscope magnifies the images of such objects thus making them visible.

Microscopes used in clinical practice use a beam of light to view specimens and thus they are called **light microscopes**. As these use two lens systems they are termed **compound light microscopes**. A compound light microscope with a single eyepiece is called **monocular**; one with two eyepieces, **binocular**.



Parts of the microscope

Practical Exercise : Identify the parts of the microscope given below:

1. Eye-piece (the ocular lens)

- It is the uppermost series of lenses through which an object is viewed.
- The lens magnifies the image formed by the objective. The magnifying power of the eyepiece is in the range 5x-20x.
- A movable pointer may be attached to the inside of the eyepiece.
- In binocular microscopes, the two eye-pieces can be moved closer or farther apart to adjust for the distance between the eyes by pulling–pushing motion or by turning a knurled ring.

2. Microscope tube

- Holds the nosepiece at one end and the eyepiece at the other end.
- It can be of the monocular or the binocular type.
- Conducts light rays.

3. Arm

- Supports the upper parts and provides a carrying handle.

4. Nose-piece

- The nosepiece is attached beneath the arm of the microscope tube.
- It carries the objectives and rotates with them.
- The objectives are arranged in sequential order of their magnifying power from lower to higher. This helps to prevent the immersion oil from getting on to the intermediate objectives.

5. Objectives (objective lenses)

- a. **Low-power objective:** holds the low power lens used to view the object (10x).
 - b. **High-power objective:** holds the high power lens used to view the object in even greater detail (40x).
 - c. **Oil immersion objective:** holds the oil immersion lens and is used in conjunction with immersion oil to view objects with the highest magnification (100x).
- The image of the specimen first passes through the objective.
 - The magnifying power is marked on the lens and is usually colour-coded for easy identification.

6. Mechanical stage

- A movable stage that aids in the accurate and steady positioning of the slide.
- The mechanical stage allows the slide to be moved to the left, right, forward or backward by rotating the knobs.
- It is fitted with fine vernier graduations as on a ruler. This helps in relocating a specific field of examination.

7. Condenser

- Focuses the light onto the specimen and illuminates it.
- It controls the amount of light and contrast.

8. Diaphragm

- Controls the amount of illumination used to view the object.

9. Light source/ Illumination

- A mirror or a built-in light source is used for illumination in the microscope.
- It directs a beam of light up through the object.

10. Coarse-adjustment knob

- Knob used to bring the object into approximate focus.
- Used only with the low-power objectives.

11. Fine-adjustment knob

- Knob used to bring the object into final focus.
- The fine focusing knob changes the distance between the specimen slide and objective very slowly and is used to view objects with high power objectives.

12. Base

- The flat surface of the microscope that rests on the table.

The magnification

The objective forms an enlarged image of the object. The eyepiece enlarges this image still more. The total enlargement or magnification is the product of the magnifying powers of the objective and the eyepiece.

For example, if the magnifying power of the eyepiece is 10x and that of the objective is 100x, the total magnification is $10 \times 100 = 1000$.

Practical exercise: Use of the light microscope

1. Ensure that the light intensity control is set to low, turn on the light and increase the brightness to give a bright light output.
2. Raise the sub-stage condenser fully and adjust the iris of the diaphragm for minimum light. (In most new models the condenser is fixed and the need to adjust it does not arise).
3. Rotate the nosepiece to get the low power objective (x10) into position i.e. above the condenser.
4. Take the stage down using the coarse adjustment control and place the specimen slide on the stage using the retaining mechanisms to hold it in place.
5. While looking carefully from a side, take the stage up close to the objective lens (do not knock the lens on the slide; this cannot normally occur when a low power objective is chosen).
6. Set the eyepieces to the correct width for your eyes so that you can look down through both comfortably.
7. Focusing: look into the eyepieces (with both eyes open) slowly lower the stage to bring the specimen into focus. Use the coarse adjustment control first and then the fine one. Slight movements of the specimen while focusing by using the mechanical stage controls, may aid you to find the object.
8. Proceed and examine the specimen under higher magnification. Depending on the specimen and the magnification used, you will need to:

- Adjust the condenser if necessary

If adjustable it should be at a low position when low power objectives are used. When changing to higher magnifications, slowly raise it up to get a sharp and crisp image (this must be done only after a specimen has been focused on the stage).

- Set the Iris Diaphragm

When the iris-diaphragm is fully opened, the image is flooded with light and definition is lost due to “white-out”. As the diaphragm is closed, controlling the amount of light passing through the condenser, the image becomes clearer and sharper as the contrast improves.

9. Using the oil immersion lens:

Once you have focused the specimen under low power, centre it in your field of view, place a drop of oil (on the illuminated spot of the slide) and bring the oil immersion lens into position. Once you have changed to the oil immersion lens, **use only the fine focus knob (fine focus adjustment) to focus.**

When light passes through glass into air it bends from the original direction. Thereby, in the microscope, the light rays bend as it is passing through the glass slide on the microscope stage into the layer of air between it and the objective lens. This limits the amount of light entering the objective and also affects its resolving power resulting in the production of a poor image. The bending effect of light is avoided by the use of immersion oil which has the same optical properties as glass. The commercially available immersion oil for microscopes has the same refractive index as glass. Thus replacing the layer of air between the lens and the slide with immersion oil gives a well defined image of the specimen.

10. Once you have finished examining:

Move the stage down and remove the slide. Change to a low power objective, reduce the light intensity to minimum and switch off the lamp.

PRACTICAL : MALARIA

PRECAUTIONS IN HANDLING A BLOOD SAMPLE

The principal blood borne diseases are:

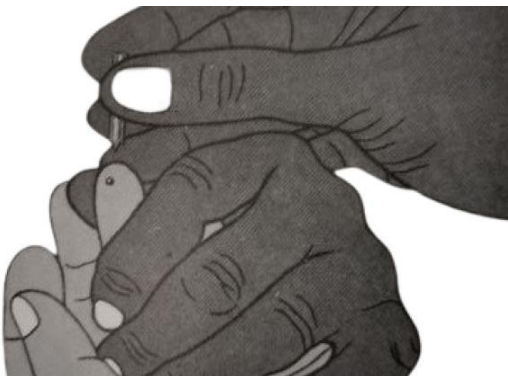- Hepatitis
- Acquired Immunodeficiency Syndrome (AIDS)
- Malaria

The collection and handling of blood samples present a potential risk of infection. This risk can be reduced by taking the following precautions:

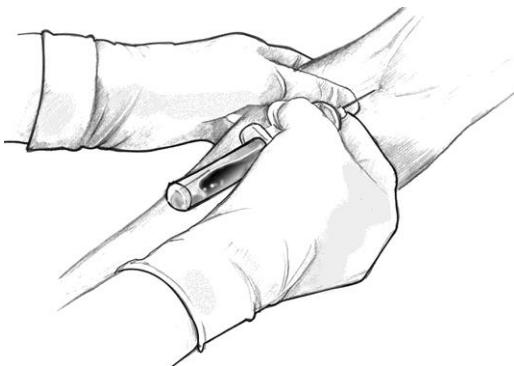
- Wear protective gloves when handling blood or taking blood samples.
- Avoid getting blood, including that from unstained slides, on your fingers or hands.
- Cover any cuts or abrasions on your hands with adhesive dressings.
- Take care not to prick yourself or others with any sharp instrument that has been in contact with blood.
- Never use disposable lancets more than once.
- Always wash your hands with soap and water after completing any task that involves the handling of blood.
- If blood does get on to your skin, wipe it off quickly with cotton wool dampened with alcohol and wash the affected area with soap and water as soon as possible.
- Any materials contaminated with blood, such as lancets, cotton swabs and discarded slides, should be boiled for 20 minutes, or placed in a solution of bleach or sodium hypochlorite (available chlorine level 10 000 parts per million), then disposed of safely by burial or incineration.

TYPE OF SAMPLE REQUIRED FOR MALARIA DIAGNOSIS

The blood for malaria parasite detection can be taken by finger prick method or by venipuncture. If venous blood is collected by venipuncture the blood is transferred to EDTA (Ethylene Diamine Tetra Acetate) tubes.



Collection of blood by finger–prick method

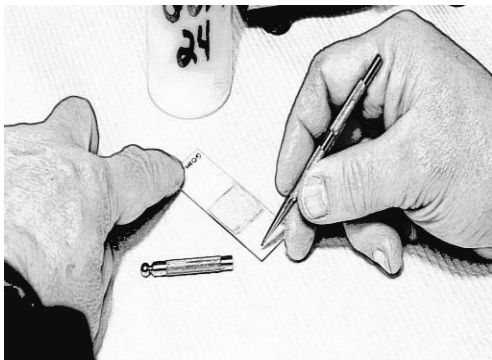


Collection of blood by venepuncture

METHOD OF CAPILLARY BLOOD COLLECTION FOR MICROSCOPY

Whenever possible the specimen should be collected before treatment. Malaria is excluded with 3 negative smears taken 12 hours apart. Further films are needed if clinical suspicion is high.

Labeling the slide



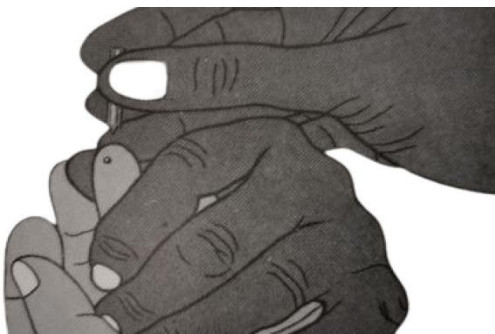Label the slide with a wax pencil by writing at one end of the slide. The label should contain the patient’ name/reference number and date

Disinfecting the finger & Stimulation of blood circulation



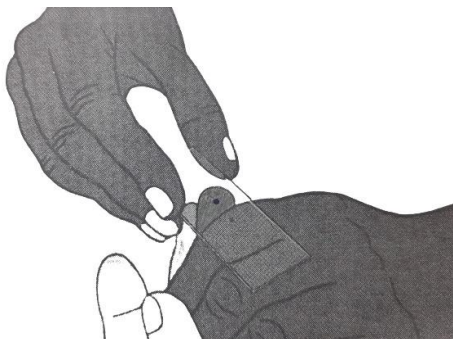
Clean and disinfect the finger with a cotton wool soaked in 70% isopropyl alcohol.

Puncturing the finger



Puncture the ball of the finger with a sterile lancet

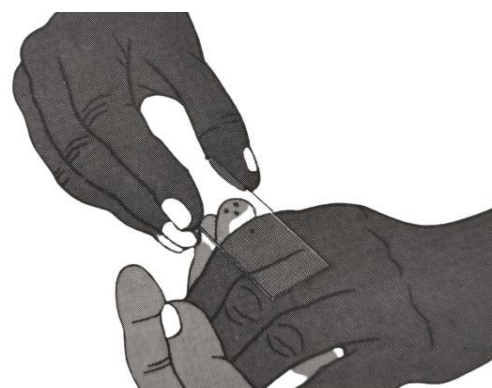Collection of blood for the thin smear



Apply gentle pressure on the finger and collect a single small drop of blood, about this size ●, on the **middle** of the slide. This is for preparation of the thin smear.

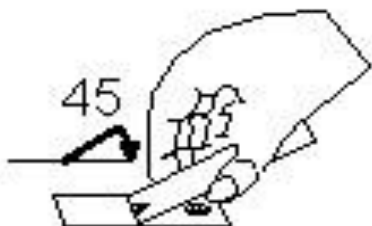

Collection of blood for the thick smear



Apply further pressure to express more blood and collect two or three larger drops, about this size ●, on the slide about 1cm inner to label.

Thin smear preparation



Wipe the remaining blood away from the finger with a piece of cotton wool.


Preparation of the thin smear: use a second clean slide as a “spreader”. Touch the small drop (in the middle of the slide) with the spreader and allow the blood to run along its edge. Firmly push the spreader along the slide, keeping the spreader at an angle of 45°. Make sure that the spreader is in even contact with the surface of the slide all the time the blood is being spread.

Thick smear preparation



Preparation of a thick smear: Using the corner of the spreader, quickly join the drops of blood and spread them to make an even, thick smear. The circular thick smear should be about 1 cm (1/3 inch) in diameter. Allow the thick smear to dry.

The smears for staining and examination looks as given below:

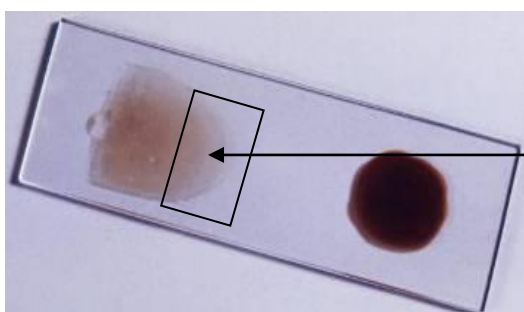


IMPORTANCE OF PREPARING THICK AND THIN SMEARS

- About 20 times more blood can be examined in a thick smear than in a thin smear in the same period of time. A thick blood smear is therefore more suitable for the rapid detection of malaria parasites. The detection of malaria parasites may not be successful by examining only a thin smear if the parasitaemia is low. Therefore, examining a thick smear is of utmost importance. In a stained thick smear, as the red cells are lysed, the intact stained parasites are readily made out against a clear background. Thick smears are also used for the estimation of parasite density.
- Thin smears are required to confirm the species and stage of the malaria parasite present. As the thin film is fixed the red cells are intact and so are the parasites within them and as such their morphology can be studied. Thin films are also suitable to calculate parasitaemia as individual cells can be easily counted.

PRACTICAL EXERCISE: USE THE MICROSCOPE AND EXAMINE THE STAINED BLOOD SMEAR PROVIDED

1. Switch on the light source.
2. Adjust the eyepieces by sliding them horizontally until they fit both eyes comfortably and the two fields merge.
3. Place the dry stained slide on the stage. Make sure that the slide is not upside down. Secure the slide to the slide holder of the mechanical stage.
4. Rotate the nose-piece to bring the 10x objective into position and raise the stage to its maximum.
5. Move the slide with the adjustment knobs to bring the tail end of the blood smear into the field of view.
6. Focus the “tail end” of the blood smear under the 10x objective using the coarse focusing knob and lowering the stage. Obtain sufficient illumination by closing or opening the iris diaphragm. For low power objectives light has to be reduced and for higher power objectives it has to be increased.



Examine the tail end of the thin blood smear where the red cells do not overlap with each other.

‘Tail end’ of the thin smear


7. Shift the 10x objective away and add a drop of immersion oil on to the illuminated spot of the smear and bring the 100x objective into position.
8. Open the iris diaphragm fully. Focus the cells using only the fine adjustment (fine focusing) knob. (Do not use the coarse adjustment knob to focus. This is to prevent any possible damage to the lens).
9. Identify the species and stage of any parasite on the smear.
10. After examination, lower the stage and swing the lowest power objective into position before removing the slide (Never attempt to remove the slide when 40x or 100x objectives are in position as this may scratch and damage the lenses).
11. Wipe off any oil from the lenses and the microscope stage using lens tissue that has been provided.
12. Switch off the microscope.

DEMONSTRATIONS

STAGES OF *Plasmodium vivax*

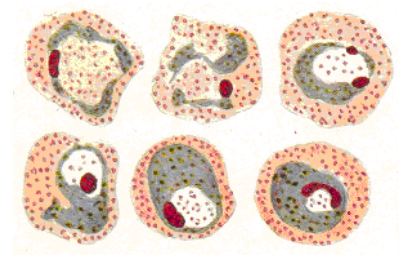
a) Ring stage – Blood smear x 1000

- Red cell enlarged
- Red cell surface may show very fine pink dots- stippling or Schuffner's dots
- With the standard stains (Giemsa's or Leishmann's) the cytoplasm stains blue and the nucleus red
- Parasite shows a coarse (thick) cytoplasm with a single nucleus (Lasts about 10-12 hours in the blood)



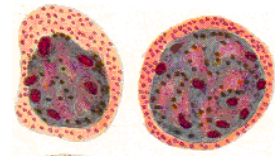
b) Amoeboid stage – Blood smear x 1000

- Red cell enlarged
- Stippling marked
- Amoeboid trophozoite with irregular cytoplasm with scattered yellow brown malarial pigment and a single nucleus (Lasts about 24 hours)



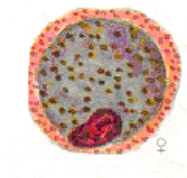
c) Mature schizont – Blood smear x 1000

- Red cell enlarged
- Stippling marked
- Pink nuclei 14-24
- Malarial pigment clumped in center



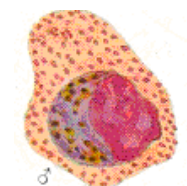d) Female gametocyte – Blood smear x 1000

- Enlarged red cell
- Schuffner's dots
- Parasite occupies almost entire cell
- Compact nucleus usually eccentric
- Evenly scattered malarial pigment



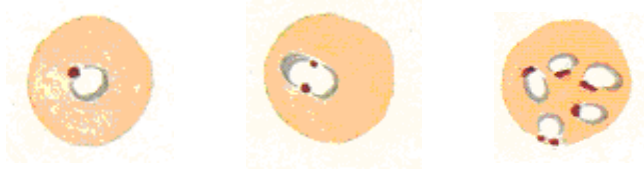e) Male gametocyte – Blood smear x 1000

- First three points as above
- Diffuse nucleus usually central
- Evenly scattered malarial pigment



STAGES OF *Plasmodium falciparum*

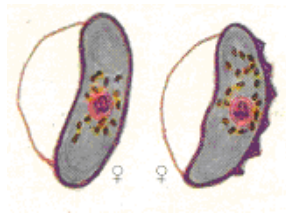
a) Ring stage – Blood smear x 1000



- Red cell not enlarged
- Clefts may be seen in the red cell: Maurer's clefts
- Small delicate thin hair like ring of cytoplasm stains blue with standard stains (Giemsa's or leishmann's) single nucleus stains red in color
- Multiple parasites may be seen inside a single red cell – Polyparasitism
- May have two nuclei in a ring - Double nuclear phenomenon
- "Accole" forms may be found closely applied to the edge of the red cell
(Ring stage lasts about 24 hours in the blood)

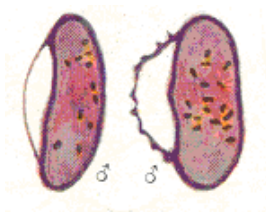The late trophozoites and schizonts of *P. falciparum* are not usually seen in peripheral blood.

b) Female gametocyte - Blood smear x 1000



- Crescent shaped, longer and more pointed than the male gametocyte
- Compact pink nucleus in center
- Surrounded by a halo of jet black malarial pigment

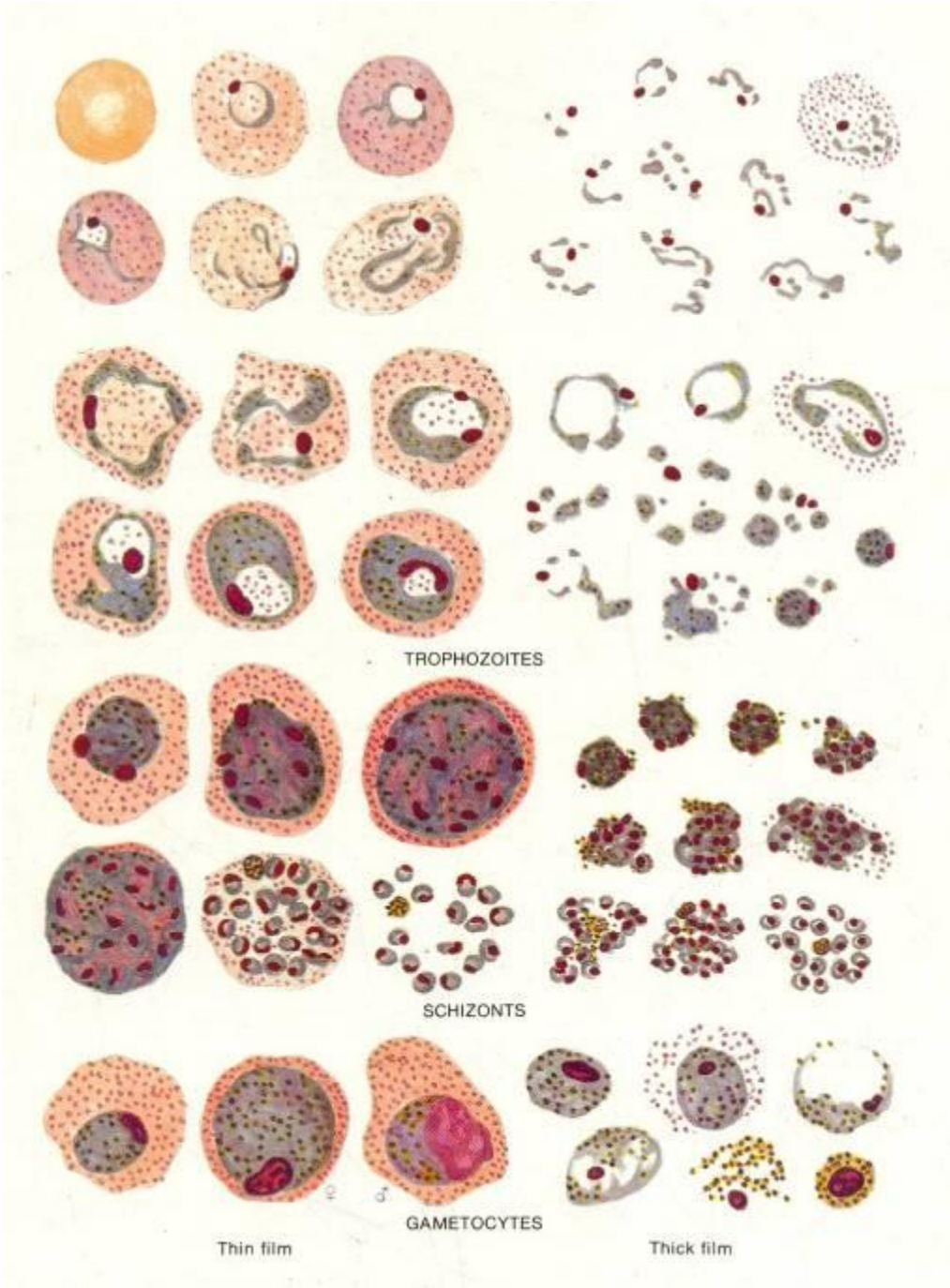c) Male gametocyte - Blood smear x 1000



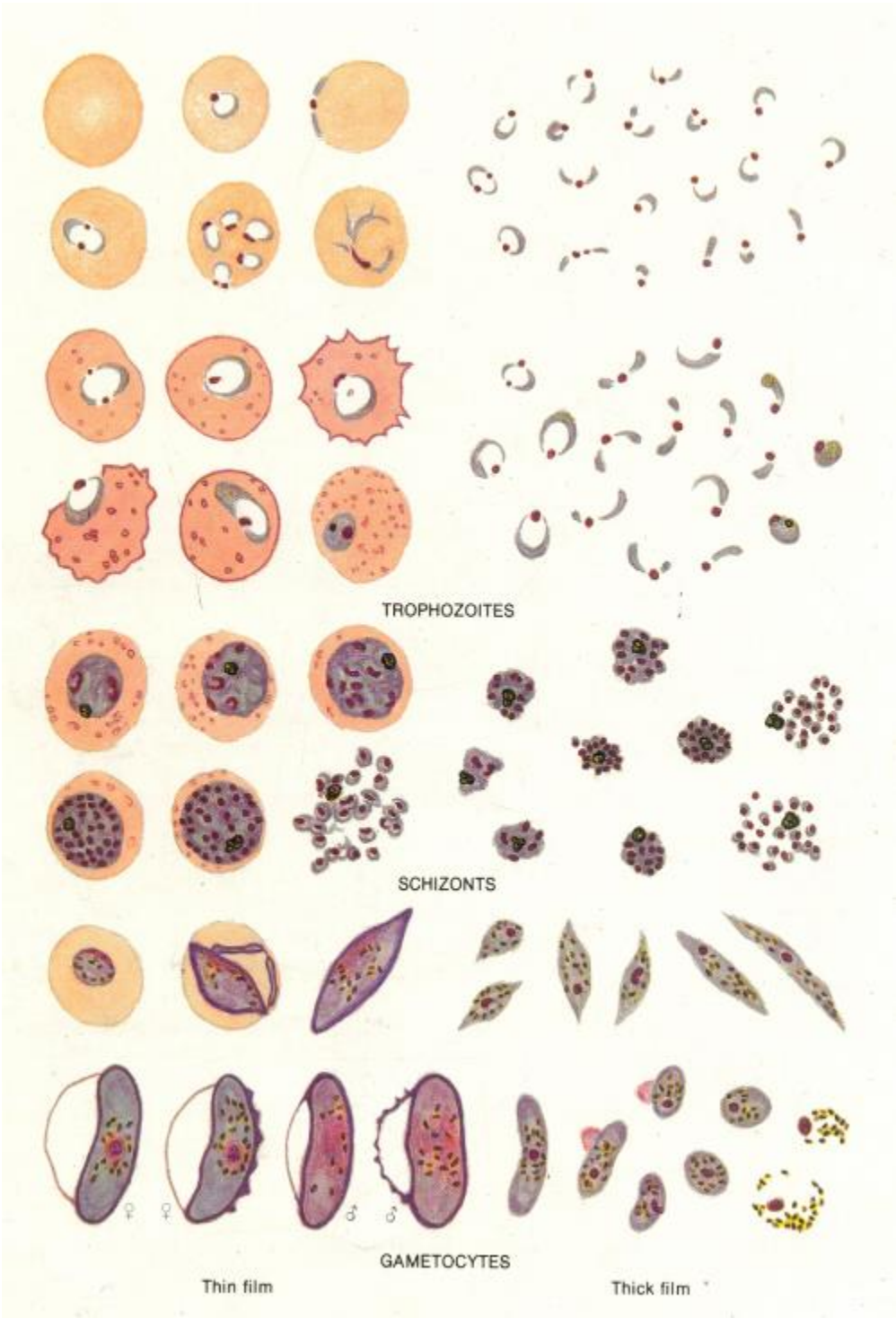
- Sausage shaped
- Rounded ends
- Diffused nucleus
- Scattered pigment

THE FOLLOWING ARE THE STAGES OF THE PARASITE THAT MAY BE SEEN WHEN EXAMINING UNDER OIL IMMERSION (X100) OBJECTIVE.

Stages of *Plasmodium vivax*



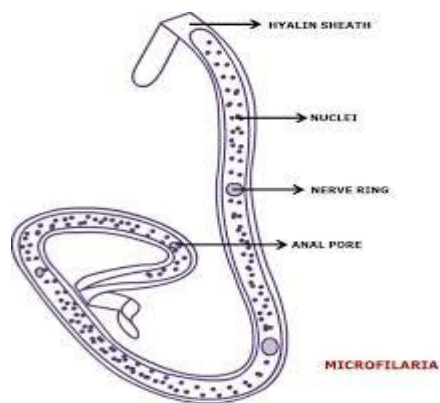
Stages of *Plasmodium falciparum*



PRACTICAL : FILARIASIS, LEISHMANIASIS, TOXOPLASMOSIS & TRYPANOSOMIASIS

FILARIASIS

Wuchereria bancrofti – microfilaria x 1000



- Smooth graceful curves
- Cephalic space square
- Body nuclei regularly arranged, discrete, countable, similar in size and shape
- Tail devoid of nuclei
- Sheath visible

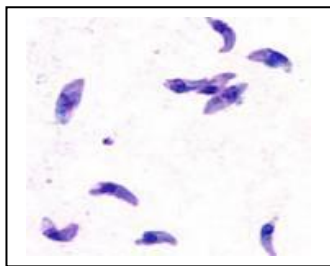
Dirofilaria repens adult – filarial worm of dog which can cause a zoonotic infection in humans.



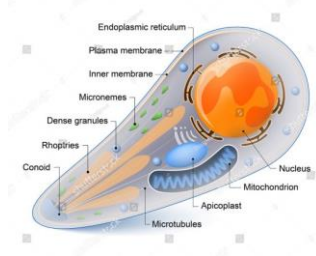
TOXOPLASMOSIS

Toxoplasma gondii

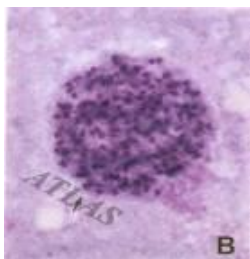
a) Pseudocysts with tachyzoites x 100



- Nuclei of macrophages stain purple
- Free crescent shaped tachyzoites with one end rounded and other end pointed



b) True cyst in brain tissue x 100



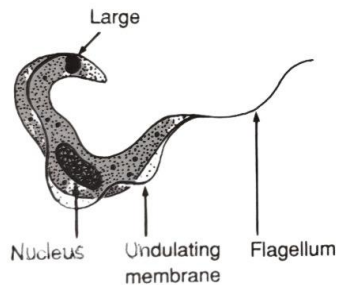
Thick walled cyst
Elongated bradyzoites with a single terminal nucleus enclosed within

TRYPANOSOMIASIS

Trypanosoma species – Trypomastigote form in blood smear x 1000

Trypanosoma gambiense and *T. rhodesiense* cause African trypanosomiasis or sleeping sickness, while *T. cruzi* is the causative agent of Chagas disease.

- Found extra-cellularly
- Spindle shaped
- Blunt posterior end and narrow anterior end
- Nucleus oval large centrally placed
- Flagellum arises from the posterior end



LEISHMANIASIS

Leishmania species - The causative agent of Visceral leishmaniasis and Cutaneous leishmaniasis belong to the genus *Leishmania*. The *Leishmania* parasite exists in two morphological forms an amastigote and a promastigote. The amastigote is the only form of parasite found in man while the promastigote is found in the sand fly gut and when *Leishmania* are cultured.

Amastigote form x 1000

- Round to oval body
- Nucleus and rod shaped kinetoplast together gives it a “dot and dash” appearance
- Found within the phagocytic vacuoles of the macrophages



Leishmania amastigotes in a macrophage

PRACTICAL : INTESTINAL AND UROGENITAL PROTOZOA COLLECTION OF FAECAL SAMPLES

Collection of appropriate faecal samples must take into account the various parasitic forms that can occur within the human gastrointestinal tract, particular attention being paid to the most convenient stage that will confirm the presence of parasites and identify species.

The irregular release of helminth ova and protozoan cysts (especially in chronic infections) makes it necessary to examine three samples routinely from each patient, on alternate days. On occasion up to six samples may be necessary in a clinically suspect case. Confirmation of successful treatment can be made by further examination of a single sample after completion of treatment.

METHOD OF COLLECTION

- Collect approximately 10g of fresh faeces uncontaminated by urine or water, using a wooden spatula, into a clean, leak-proof, wide-mouthed container with a screw cap e.g. yogurt cup.
- The container should be free from antiseptics and disinfectants.
- Label the samples clearly with the patient's name, reference number, date and time of collection. All samples should be accompanied by a request form, from the physician giving the relevant clinical details and recent travel history.
- Samples and forms from patients with confirmed or suspected diagnosis of certain infectious diseases such as AIDS or hepatitis should be clearly labeled with a 'risk of infection' "Biohazard" vinyl tape.
- Most viable parasites are susceptible to desiccation or temperature variation. If the time lapse between collection and observation is considerable, depending on the parasite, it may be necessary to add some form of preservative to the faeces to retain the morphology as near to the original as possible. Formed samples can be kept in a refrigerator at + 4° C for a short while, but not in an incubator. Whole worms or segments passed should be placed in a separate container.

DELIVERY AND TRANSPORTATION

- Formed faecal samples without evidence of blood or mucus should be examined during the day of passage. It is possible to store these samples for up to 4 hours at + 4° C.
- Soft, unformed or liquid faecal samples and those containing blood or mucus may contain vegetative, trophozoite forms of protozoa. These samples should be delivered to the laboratory with the minimum of delay, preferably within 30 minutes to 1 hour of collection. (Amoebic trophozoites may still be active in unformed faeces up to several hours after passage but the time depends on the external temperature and is unpredictable).

MACROSCOPIC EXAMINATION OF STOOLS

a) Consistency

Faecal consistency varies with diet but certain clinical conditions associated with parasite presence may be suggested by particular consistencies. The presence of protozoal trophozoites in the stools will depend on the consistency and the frequency of passage of faeces. Trophozoites are more likely to be found in (ii) or (iii) and cysts in (i).

Stools should be recorded as:

- (i) **Formed** : Normal shape and consistency. Formed stools from which the water content has been reabsorbed will contain few trophozoites and principally the cyst stage of protozoa.
- (ii) **Semi-formed or unformed** : Soft faeces with no regular shape.
- (iii) **Liquid** : Note colour and any flakes of mucus or blood present.

b) Composition

The stool may contain blood and mucus as evidence of ulceration or colitis due to invasive amoebae, bacillary dysentery or inflammatory bowel conditions. It may also indicate occult blood from gastric ulcers or conditions such as giardiasis. It may also have pus, froth, undigested food, vegetable fibres, fat etc.

Faeces may contain adult helminthes such as *Ascaris lumbricoides*, *Enterobius vermicularis* or segments of *Taenia* sp. Gravid *Taenia* segments are frequently motile for several days and may migrate to the top of the container.

c) Colour

Pale yellowish stool are passed in steatorrhoeac conditions such as giardiasis or tropical sprue. Dark or black stools occur when iron or bismuth is taken or when there is intestinal haemorrhage.

d) Smell**e) Amount****MICROSCOPIC EXAMINATION OF STOOLS****DIRECT MICROSCOPY OF STOOLS**

Direct microscopy is used to observe cellular exudate and motile protozoan trophozoites, as they are killed or distorted during concentration techniques. The presence of other parasitic stages, undigested food, bacteria, yeasts, crystals or fat globules are also noted. All fresh stools (less than 4 hours old) which are semi formed, unformed, liquid or show the presence of blood and / or mucus should be examined by direct microscopy. Routine direct microscopy on formed stools is unnecessary unless there is external blood or mucus. Any blood or mucus present should be examined separately as it is more likely to contain trophozoites. Trophozoites die rapidly, so unformed stools should be looked at as soon as possible after voiding, preferably within 30 minutes of being passed.

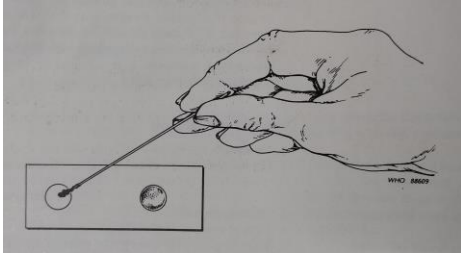
Preparation of saline and iodine wet mounts for direct microscopy of stools***Materials and reagents***

1. Wooden applicator sticks or matches
2. Microscope slides (75x25 mm)
3. Cover slips
4. Pens or markers for indelible labeling
5. Dropping bottles containing:
isotonic saline solution (0.85%; 8.5 g/l)*
Lugol's iodine (1% solution)

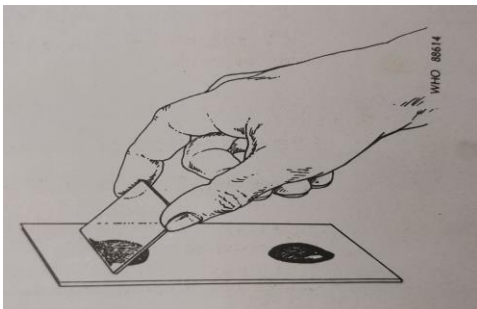
Procedure

1. With a wax pencil or marker, write the patient's name or identification number and the date at the left-hand end of the slide.
2. Place a drop of saline in the center of the left half of the slide and place a drop of iodine solution in the center of the right half of the slide (Note: iodine wet mount preparations are most useful for protozoa, less so for helminths).

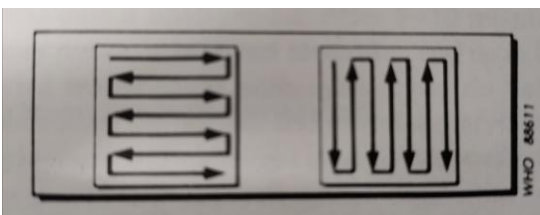
3. With an applicator stick or match, pick up a small portion of faeces (approximately 2 mg which is about the size of a match head) and add it to the drop of saline: add a similar portion to the drop of iodine. Mix the faeces in each drop until a suspension is formed.



4. Cover each drop with a cover slip by holding the cover slip at an angle, touching the edge of the drop, and gently lowering the cover slip onto the slide so that air bubbles are not produced (Note: ideal preparations containing 2 mg of faeces are uniform – not so thick that faecal debris can obscure organisms, nor so thin that blank spaces are present)



5. Examine the preparations with the 10x objective or, if needed for identification, the high power objective of the microscope (40x), in a systematic manner (either up and down or laterally) so that the entire cover slip area is observed. When organisms or suspicious objects are seen, switch to higher magnification for more detailed morphology of the object in question.



DISPOSAL

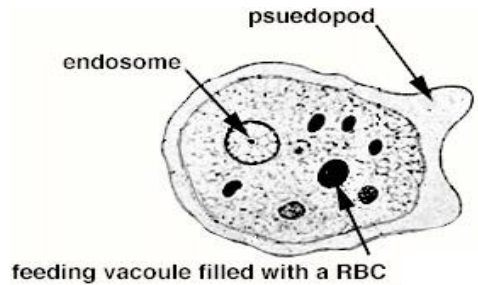
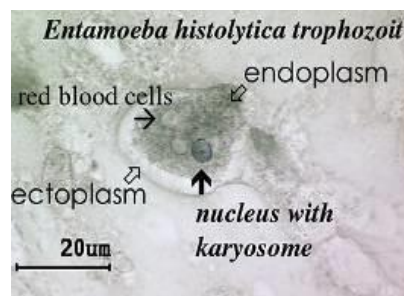
1. Discard slides, coverslips and ekel applicators into 1% aqueous lysol in a wide mouthed container. Slides and coverslips are cleaned and reused as given in the following step while the applicators are thrown away. Since coverslips are fragile these are collected and cleaned separately.
2. Keep overnight.
3. Wash in running tap-water for 1 hour.
4. Boil in soap water (65g of soap in a gallon of water) and let cool to room temperature.
5. Wash in running tap-water for 1 hour.
6. Wipe dry with clean cloth and use.

DEMONSTRATIONS

1: *ENTAMOEBA HISTOLYTICA* X 1000

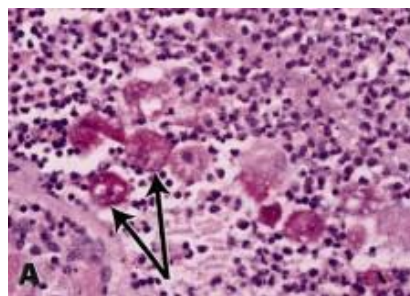
a) Trophozoite in iron haematoxylin stain x 1000

- Outer ectoplasm wide and clear, inner endoplasm is finely granular and “ground glass” like in appearance.
- Pseudopodia visible
- Ingested red blood cells present
- Nucleus with uniform peripheral chromatin and centrally located karyosome



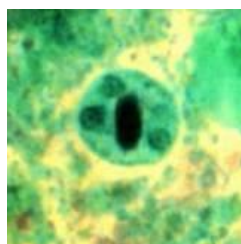
b) Trophozoite in a tissue section x 1000

- Trophozoites with ingested RBC
- Nuclei of intestinal epithelial cells

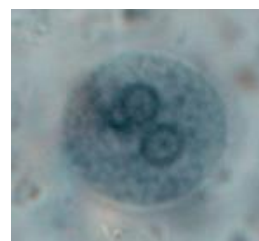
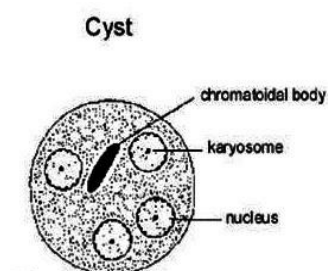


c) Cyst in Trichrome stain x 1000

- Sausage shaped chromatoidal bodies stain red
- Cytoplasm stains bluish green to purple.
- Nuclei < 4
- Glycogen vacuoles



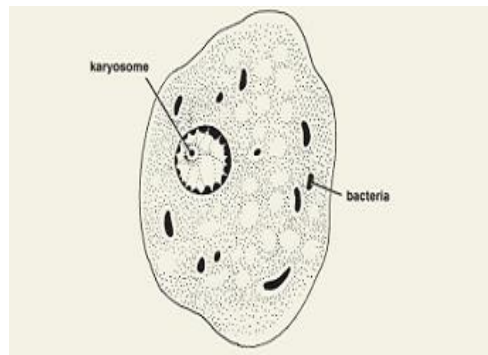
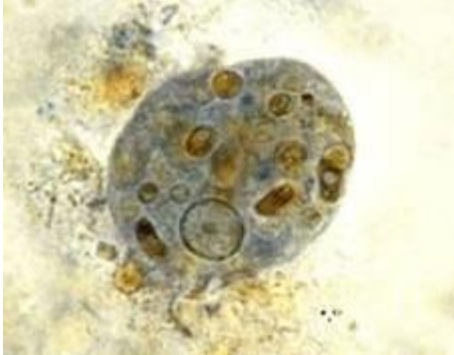
d) Cyst in Iron Haematoxylin stain x 1000



2. *ENTAMOEBIA COLI* X 1000

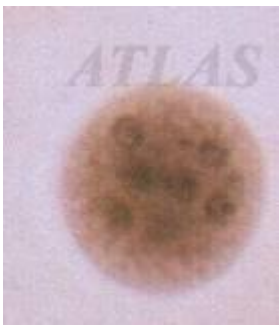
a) Trophozoite in iron haematoxylin stain x 1000

- Ectoplasm is granular and less well differentiated from endoplasm
- Endoplasm is more granular and more vacuolated
- May contain bacteria, yeast (rarely red blood cells)
- Pseudopodia have more sluggish movements
- Nucleus has heavier peripheral chromatin and a larger eccentric karyosome

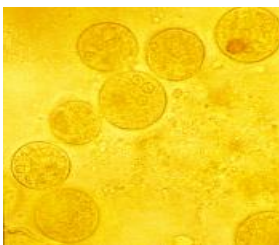

b) Cyst in Iodine x 400

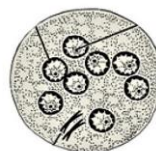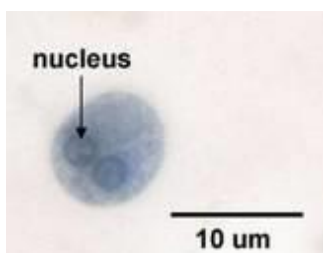
- Generally larger than *E. histolytica*
- Chromatoidal bodies if present are splinter like with pointed ends
- Glycogen vacuole in immature cyst may be more heavily stained brown
- Contains 1-8 nuclei



c) Cyst in Saline x 400

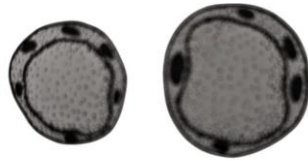


d) Cyst in Iron Haematoxylin stain x 1000



3. *BLASTOCYSTIS HOMINIS* - Iron Haematoxylin x 1000

- Central vacuole
- Nuclei darkly stained
- Cytoplasm visible
- Outer cell membrane



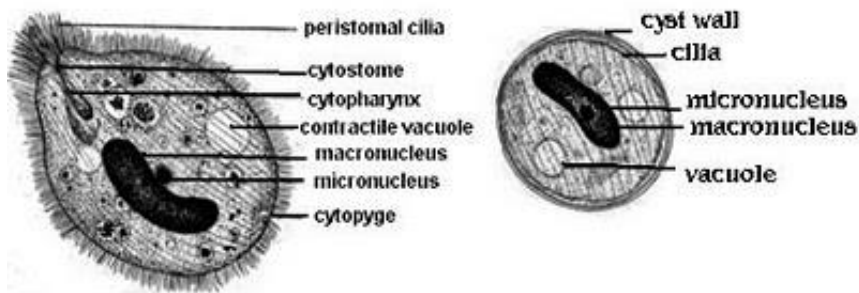
4. *BALANTIDIUM COLI*

a) Trophozoite x 1000

- Cilia visible
- Kidney shaped macronucleus
- Rounded micronucleus

b) Cyst x 1000

- Round in shape
- Large macronucleus
- Smaller micronucleus
- Cilia may be faintly visible

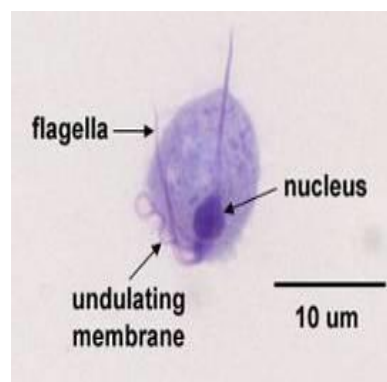
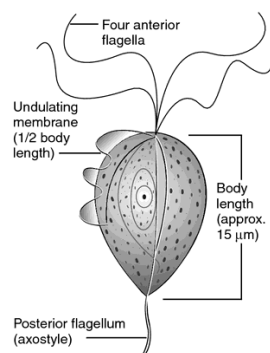


5. *TRICHOMONAS VAGINALIS*

Trophozoite x 1000

- Oval in shape
- 3-5 anterior flagellae
- Undulating membrane extends more than half of the body length
- An axostyle
- Nucleus in anterior part of body

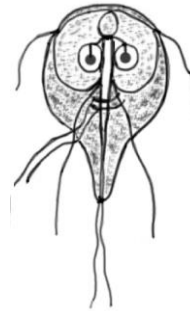
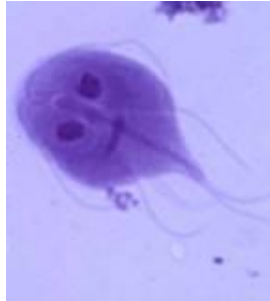No cyst stage



6. *GIARDIA INTESTINALIS*

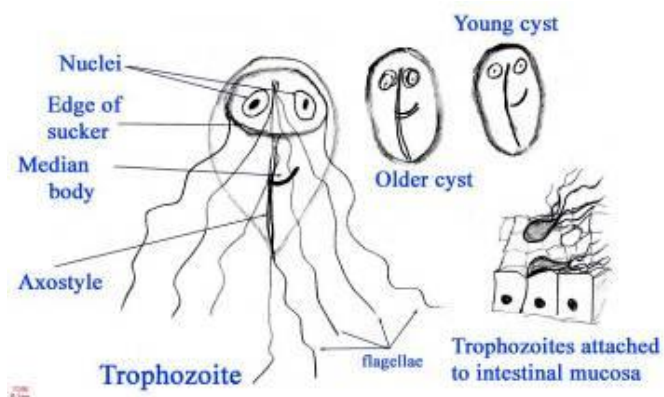
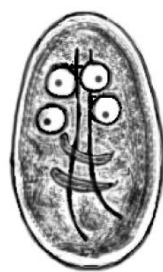
a) Trophozoite x 1000

- Pear shaped
- Bilaterally symmetrical
- Ventral surface has a sucking disc
- 4 pairs of flagella present
- Nuclei visible



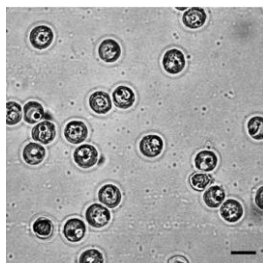
b) Cyst in wet mount x 1000

- Cyst wall present
- 2-4 nuclei
- Contains the remains of axonemes and parabasal bodies



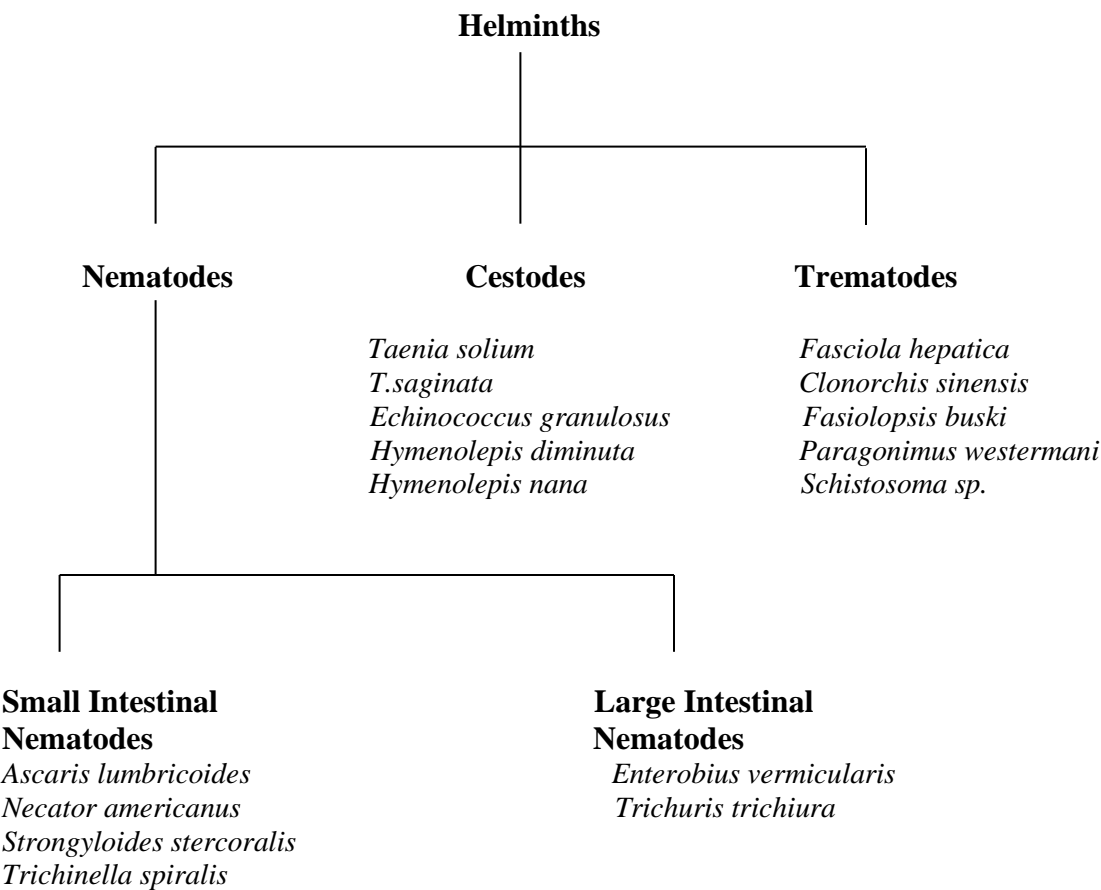
7. *Cryptosporidium oocyst* - Ziehl-Neelsen stain x 1000

- Small, round in shape about 4µ in diameter.
- A mature oocyst contains 4 sporozoites.



PRACTICAL - INTESTINAL NEMATODES

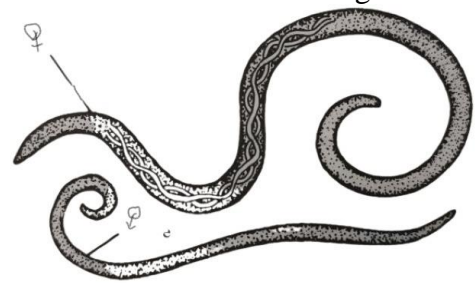
CLASSIFICATION



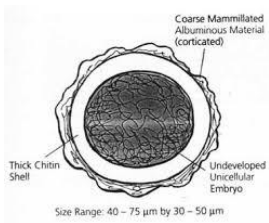
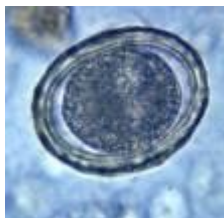
NEMATODES

1. ASCARIS LUMBRICOIDES (ROUND WORM)

- a) Adult male and female worm (gross)
- Posterior end curved in males 10-30 cm in length
 - Females are 20-40 cm in length




- b) Fertilized egg x 400
- Round or oval in shape
 - Outer albuminoid layer is coarsely mammillated
 - Thick transparent glycogen middle layer (hyaline shell)
 - Unsegmented ovum



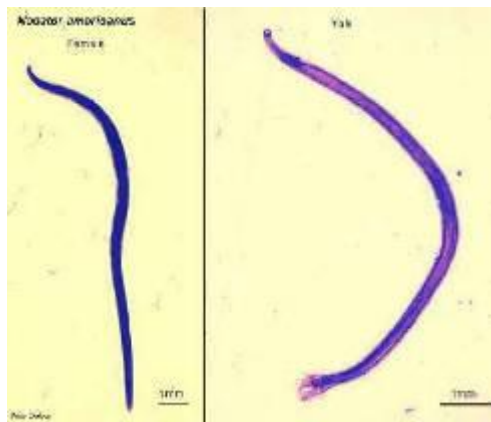
c) Unfertilized egg x 400

- Longer and narrower than the fertilized egg (barrel shaped)
- Thinner mammillated outer coat
- Thinner shell
- Amorphous mass of disorganized granules inside
- No clear demarcation of layers



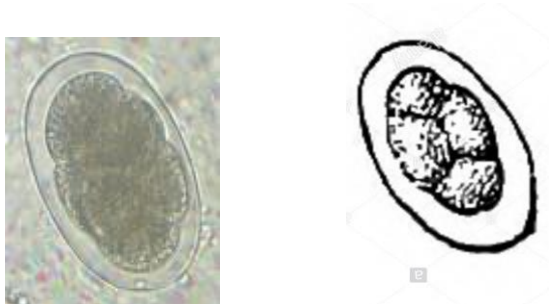2. *NECATOR AMERICANUS* (HOOKWORM)

- a) Adult male or female (universal low power)
- Head curvature opposite to body curvature
 - Small cylindrical worm
 - Tapering anteriorly
 - Approximately 1cm long



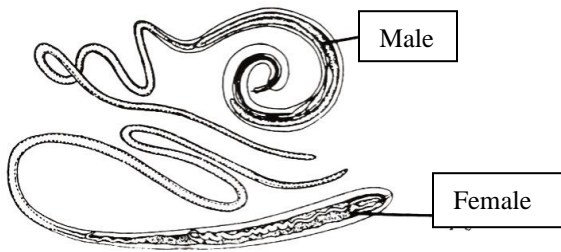
b) Hookworm egg x 400

- Broadly oval with bluntly rounded ends
- Colourless
- Thin walled
- Segmented ovum

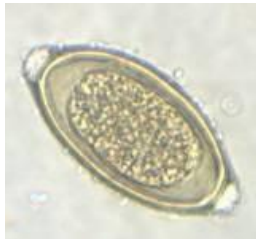

3. *TRICHURIS TRICHIURA* (WHIP WORM)

- a) Adult male and female worms (gross specimen)
- Posterior end bluntly rounded in the female and curved in the male

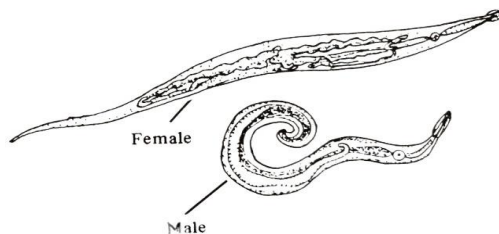


- b) Whipworm egg x 400
- Like a paddy seed
 - Outer coat is bile stained and appears brown in colour
 - At either end there are transparent polar prominences (mucoid plug)

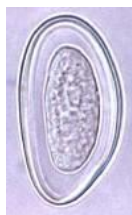

4. *ENTEROBIUS VERMICULARIS* (PINWORM)

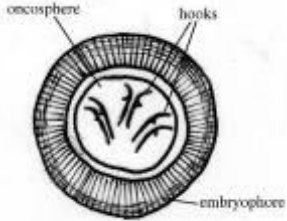
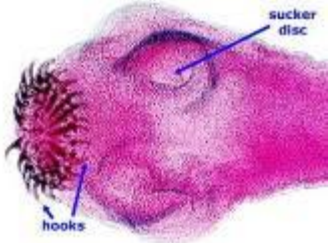
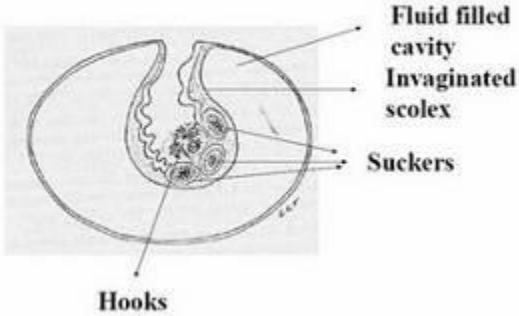
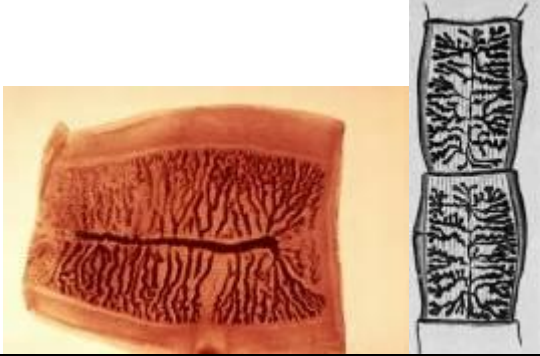
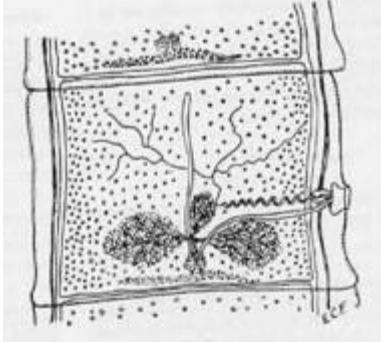
- a) Adult male and female (gross specimen)
- Spindle shaped

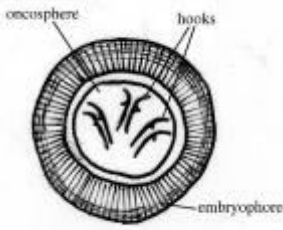

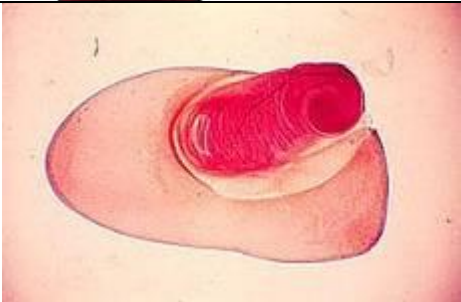
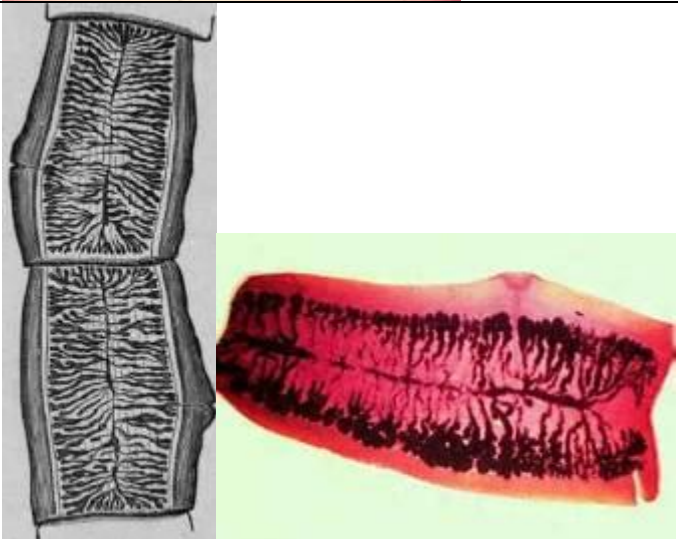
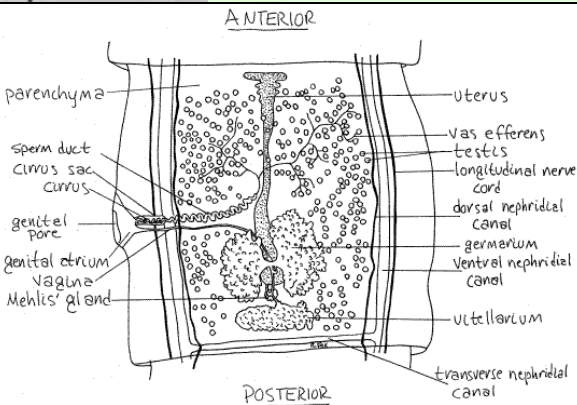





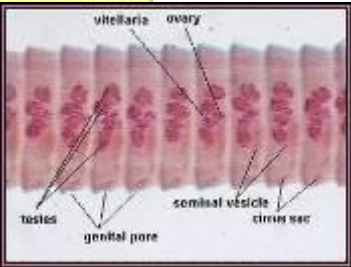

- b) Pinworm egg x 400
- Plano-convex
 - Thick double wall colourless
 - Rhabditiform larva present inside



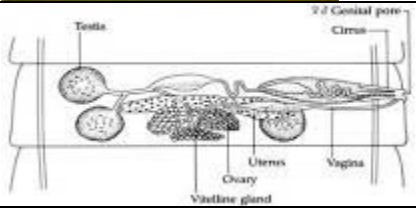



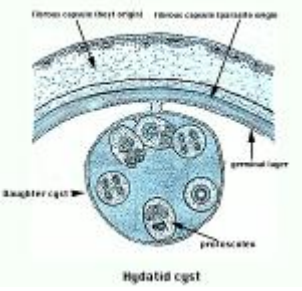

CESTODES

TAENIA SOLIUM	Adult worm: genital pore situated laterally, no uterine pore	
	Taenid egg: Spherical, very thin, hyaline outer membrane, embryophore with six hooklets insite	
	Scolex: globular, 4 cup shaped suckers, projection like a beak (rostellum), 2 rows of hooks at the base of the rostellum.	
	Cysticercus cellulosae: thin walled cyst, invaginated scolex with suckers and chitinized hooks	<div>Diagrammatic representation of a cysticercus</div> 
	Gravid proglottid: central uterus, <12 lateral branches	
	Mature segments: square shaped, lateral pore.	

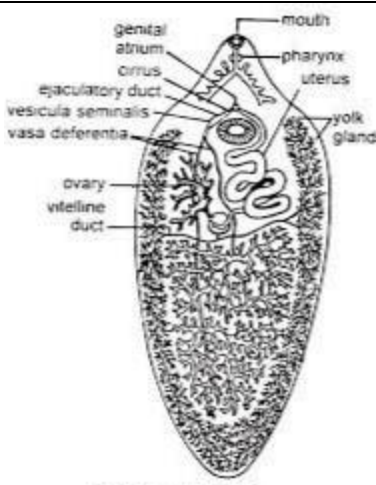
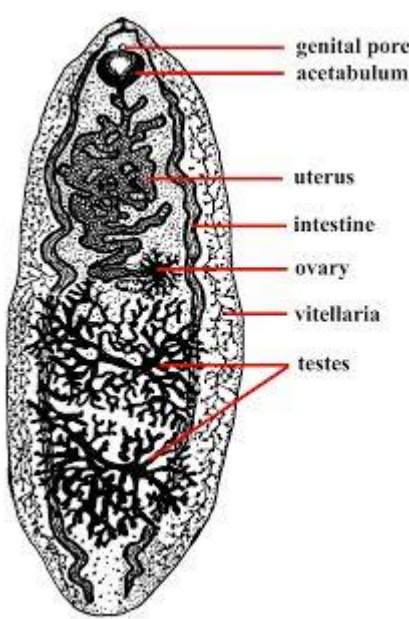
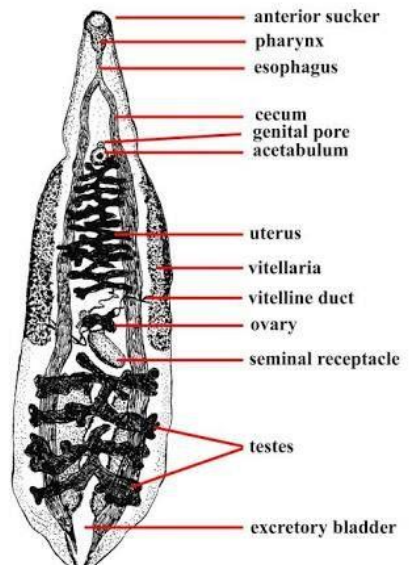
TAENIA SAGINATA	Adult worm: genital pore situated laterally, no uterine pore	
	Taenid egg: Spherical, very thin, hyaline outer membrane, embryophore with six hooklets inside	
	Scolex: quadrate, 4 suckers, no rostellum, no hooks	
	Cysticercus bovis: cyst like structure, protoscolices visible. thin walled cyst, invaginated scolex with suckers and chitinized hooks	
	Gravid proglottid: contains uterus with eggs, >12 lateral branches, lateral genital pore	
	Mature segments: square shaped, lateral pore, Similar to <i>T.solium</i> mature proglottids.	

HYMENOLEPIS DIMINUTA <i>Rat Tape Worm</i>	Egg: spherical, onchosphere with 6 hooklets	
	Scolex: club shaped, retractable, rostellum, 4 small suckers, no hooks	
	Cysticercoid larvae: tailed larvae	
	Mature proglottid: Rhomboid shaped 3 round testes, bi-lobed ovary and lateral genital pore	
	Gravid segment: contains uterus with eggs, 4mm in length, broad	

HYMENOLEPIS NANA <i>Dwarf Tape Worm</i>	Egg: oval shaped, hyaline outer shell, inner membrane, polar filaments, hexacanth embryo	
	Scolex: globular, retractable rostellum with single row of small hooks, 4 suckers	
	Mature Proglottid: broad, bilobed ovary, 3 round testicles in each segment, lateral genital pore	
	Gravid proglottid: long, 0.6 mm in length, filled with eggs	

<p><i>ECHINOCOCCUS GRANULOSUS</i> <i>Dog Tape Worm</i></p>	<p>Adult worm: scolex has a rostellum armed with hooks arranged in two rows, 1-2 immature segments, a single gravid segment half the body length containing a branched uterus</p>	
	<p>Hydatid cyst in section: with 3 coverings (pericyst, ectocyst, endocyst), a brood capsule and protoscolices</p>	
	<p>Protoscolices: cyst with invaginated scolex, scolex with double crown of hooklets and four suckers</p>	

TREMATODES

<p><i>FASCIOLA HEPATICA</i> Leaf like caecae heavily branched Testis in tandem position Ovary to the right of the midline Coiled uterus</p>	 <p>genital atrium cirrus ejaculatory duct vesicula seminalis vasa deferentia ovary vitelline duct mouth pharynx uterus yolk glands</p> <p>Fig. 22.9. Fasciola hepatica.</p>
<p><i>FASCIOLOPSIS BUSKI</i> Intestinal caeca not branched with two characteristic lateral indentations Testis in tandem position, ovary at the centre to the right of the midline</p>	 <p>genital pore acetabulum uterus intestine ovary vitellaria testes</p>
<p><i>CLONORCHIS SINENSIS</i> Narrow anterior end, round posterior end Unbranched caeca Testis in tandem position, ovary anterior to the testis in midline</p>	 <p>anterior sucker pharynx esophagus cecum genital pore acetabulum uterus vitellaria vitelline duct ovary seminal receptacle testes excretory bladder</p>

PRACTICAL – ARTHROPODS

CLASSIFICATION

Phylum

Arthropods

Class

Insecta

Arachnida

Order

Anoplura
(lice)

Diptera
(flies)

Siphonaptera
(fleas)

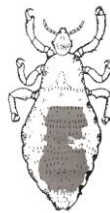Hemiptera
(bugs)

Acarina
(ticks and mites)

1. LICE

a) *Pediculus humanus capitis* (head louse)

b) *Pediculus humanus corporis* (body louse)



Adult x 100

- Flattened dorsoventrally
- Tip of abdomen bifurcated – “w” shaped in females
- Tip of abdomen not bifurcated in the male
- Abdomen has 7 segments

Egg (Nit) x 100

- Operculated
- Cemented to fibers of clothing (or hairs)
- Whitish in colour

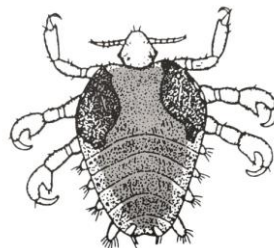
Medical importance

1) Are vectors of

- Louse borne epidemic typhus due to *Rickettsia prowazeki*
- Trench fever due to *Bartonella quintana*
- Louse borne relapsing fever due to *Borrelia recurrentis*

2) Causes pruritus

c) *Phthirus pubis* (crab louse)



Adult x 100

- Smaller than the body louse
- Less differentiation between the thorax and abdomen
- 3 pairs of legs
- 1st pair of legs more slender with smaller claws
- In the female the tip of the abdomen is bifurcated – “w” shaped

2. FLIES

a) *Musca domestica* (house fly)

Adult

- 6-9 mm in length
- Four broad dark longitudinal stripes on thorax on dorsal aspect
- Wings- 4th vein bends sharply to join the costa near the 3rd vein.

Egg

- Creamy white
- 1mm in length
- Banana shaped
- Two rib like thickenings along its dorsal surface

Larva x 40

- 12 segments
- Tapers gradually towards the anterior end
- First segment has a pair of mouth hooks

Medical importance

- House fly adult acts as a mechanical vector and transmits disease
- House fly larvae have occasionally caused urogenital and traumatic myiasis



b) *Glossina* (tsetse fly)

Wing- There is a closed cell “hatchet cell” between the 4th and 5th veins

Medical importance

- Transmits African Trypanosomiasis (sleeping sickness)

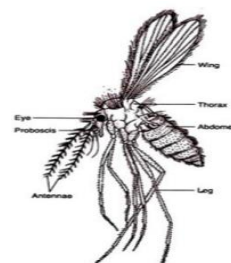


c) *Phlebotomus* (sand fly)

- Hairy
- Three very long pairs of legs
- Head bent acutely down
- Large black eyes
- wings kept erect “V”- shaped when at rest
- 2nd vein divided
- Found in Sri Lanka

Medical importance: Transmits

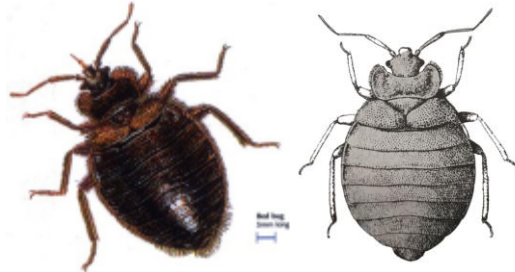
- Leishmaniasis
- Sand fly fever (viral)
- Oroya fever (*Bartonella* species)



3. BUGS

a) *Cimex lectularius* (bed bug)

- Pyramidal shaped flattened head
- Head has prominent compound eyes
- Oval dorsoventrally flattened body
- Tip of abdomen bifurcated in female – “w” shaped
- Tip of abdomen not bifurcated in males – “v” shaped
- Each of the 3 thoracic segments bear a pair of legs that terminate as claws



b) *Reduviid bug*

- Long narrow head
- Prominent compound eyes
- Long antenna
- 3 segmented proboscis
- Dark brown in colour

Medical importance

- Transmits Chagas disease (American trypanosomiasis)

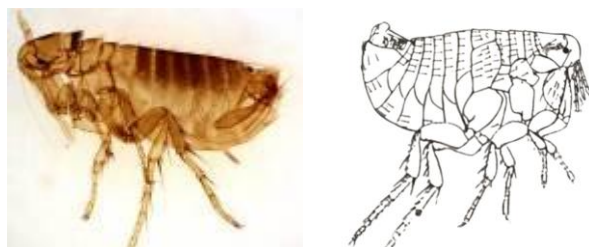


4. FLEAS

Medical importance

Acts as a vector of disease

- Bubonic plague - caused by the bacillus *Yersinia pestis*
- Endemic typhus - caused by *Rickettsia typhi*
- Cestode infections - *H.diminuta*, *Dipylidium caninum*



5. TICKS

Hard ticks & Soft ticks



Medical importance

- 1) Acts as a vector for diseases
 - a) Rickettsial diseases
 - Rocky mountain spotted fever by *R.rickettsiae*
 - Tick borne typhus
 - Q fever- *Coxiella burnetti*
 - b) Viral diseases
 - Colorado tick fever
 - Kyasanur forest disease
 - c) Bacterial and spirochaete disease
 - Tick borne relapsing fever
 - Lyme disease - *Borrelia burgdorferi*
 - Tularemia - *Francisella tularensis*
 - d) Protozoal disease- Babesiosis

6. MITES

a) *Sarcoptes scabiei*

Adult x 100

- Whitish, disc shaped and dorso-ventrally flattened
- 4 pairs of short stumpy legs

Medical importance

- e) Lesions appear as itchy papules at sites of each mite and later develop into pustules due to secondary infections.
- f) Secondary infection of lesions by *B.haemolytic* Streptococci can result in glomerulonephritis.



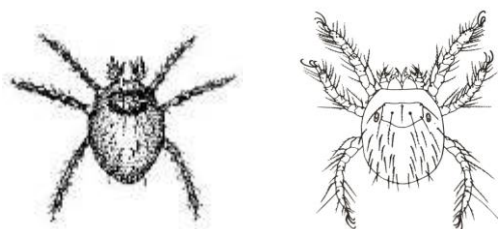
b) Trombiculid mite

Larva x 100

- Reddish orange
- 3 pairs of legs
- On dorsal surface a rectangular plate / scutum bearing feathered septae together with 2 flagelliform sensillae

Medical importance

- Vector for *Rickettsia tsutsugamushi* which causes scrub typhus



MOSQUITOES

1. *Anopheles culicifacies* (transmits malaria)

Adult x 40

- Anterior border of wing has 4 sharply defined pale areas and a 5th at the wing tip



2. *Culex spp.*

Adult x 40

Culex quinquefasciatus (transmits bancroftian filariasis)

Culex gelidus (transmits Japanese Encephalitis)

- Absence of any positive markings characteristic of *Culex* species



3. *Mansonia species* (vector of *Brugia malayi* in South and South East Asia, transmits *Dirofilaria repens* to humans)

Adult x 40

- Wings covered with flat, broad, light and dark scales giving the wings a speckled (salt and pepper) appearance



4. *Aedes species* (transmits yellow fever, dengue fever, dengue haemorrhagic fever, *Dirofilaria repens*)

Adult

- Black in colour
- Silvery scales on body
- Legs show a banded appearance

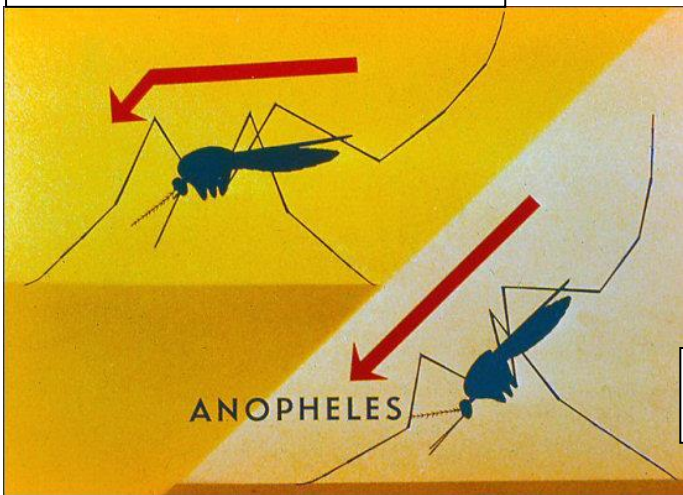


Aedes aegypti- thorax shows a silvery lyre shaped marking on the dorsal surface.



Aedes albopictus – shows a “I” shaped mark on thorax.

Culicine species adult mosquitoes lie horizontal to the surface



Anopheles adult mosquito lies at a 45 degree angle





PRACTICAL : SNAKES
1. ELAPIDS


Ceylon cobra
Naja naja naja







Special Features

- Largest elapid up to 6 feet
- Light and dark brown or blackish in colour with a white speckled appearance along the length of the body.
- The vertebrals are not enlarged.
- Sub-caudals are divided (biserial).
- Only hooded snake found in Sri Lanka (hood found between head and body).
- Characteristic spectacle shaped marking on dorsal surface just below head.

Ceylon krait <i>Bungarus ceylonicus</i>	Special Features
	Brownish black or black with broad white bands on the dorsum which are continued on the belly (on the ventral aspect)
	Oval head
	Vertebrals enlarged
	Subcaudals undivided

Common krait (<i>Bungarus caeruleus</i>) 	Special Features
	Black glossy snake oily appearance
	Vertebrals enlarged
	Sub-caudals undivided Thin white bands in pairs on the dorsum only. No bands on the belly. Belly is whitish.




2. VIPERS

<p>Russell's viper (<i>Vipera russelli</i>)</p> 	<p>Special features</p> <p>3 longitudinal rows of characteristic oval/round markings along the length of the body. One row runs along the median dorsal line and other two on either side. Each spot is dark brown with an inner black and outer white margin.</p>
<p>Saw scaled viper (<i>Echis carinatus</i>)</p> 	<p>Characteristic dagger shape or “Bird’s foot” marking on the head</p> <p>Serrated costal scales on both sides of the body</p> <p>Dorsally the colour is brown with dark blotches and a wavy line on the side of the body.</p>
<p>Hump nosed viper (<i>Hypnale</i> spp)</p> 	<p>Large head scales which is an exception from the other vipers.</p> <p>The snout ends in a hump like prominence.</p> <p>Typical brown mottled appearance with a series of brown oval spots on either side of the spine.</p>
<p>Green pit viper (<i>Trimeresurus trigonocephalus</i>)</p> 	<p>A black stripe runs from the eye to the angle of jaw on each side.</p>





***Pit vipers**

The hump nosed viper and Green pit viper are referred to as the pit vipers due to the presence of the Loreal pit on the head between the nostrils and the eye on either side. These are sensitive thermal receptors which help to locate warm blooded prey.

3. COLUBRIDES

<p>Cat snake <i>Boiga spp</i></p> 	<p>Special features</p> <p>Conspicuous neck which makes the head look triangular. Brown mottled appearance with a series of brown oval spots on either side of spine, similar to the body markings of the Hump nosed viper. A long thin tail.</p> <p>No hump on the head</p>
<p>The Ceylon Wolf snake (<i>Cercaspis carinatus</i>)</p> 	<p>Looks morphologically similar to the Sri Lankan Krait.</p> <p>Subcaudals undivided</p> <p>Vertebrals are not enlarged.</p>
<p>Rat snake (<i>Ptyas mucosa</i>)</p> 	<p>Large snake. Grows up to 6 feet. Belly is whitish yellow Subcaudals biserial</p>

4. OTHER IMPORTANT SNAKES

<p>Python (<i>Python molurus</i>)</p> 	<p>Quadrangular patches on body Non venomous Can kill the victim by constriction.</p>
<p>Earth snake</p> 	<p>Earth worm like. Non venomous</p>
<p>Sea snake (<i>Hydrophis ornatus ornatus</i>)</p> 	<p>Its head is small with a slender neck. The body is flattened from side to side Have a paddle like (laterally compressed) tail with a rounded end</p>
<p>Fresh water snakes (<i>Cerberus rhynchops rhynchops</i>)</p> 	<p>Body and tail are cylindrical</p>

